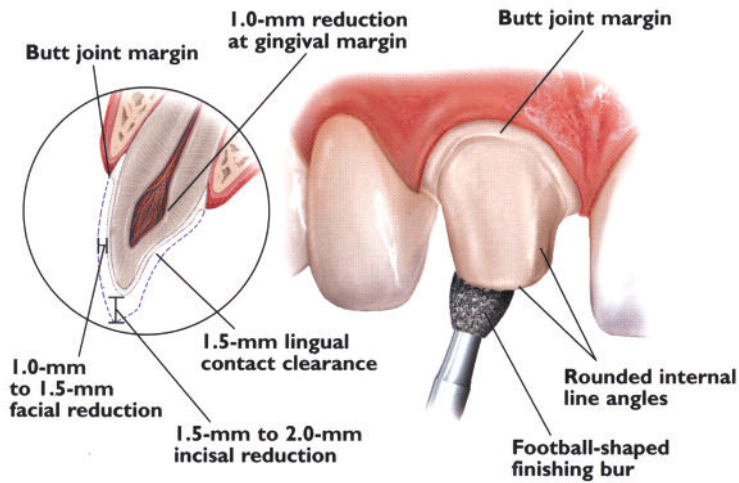




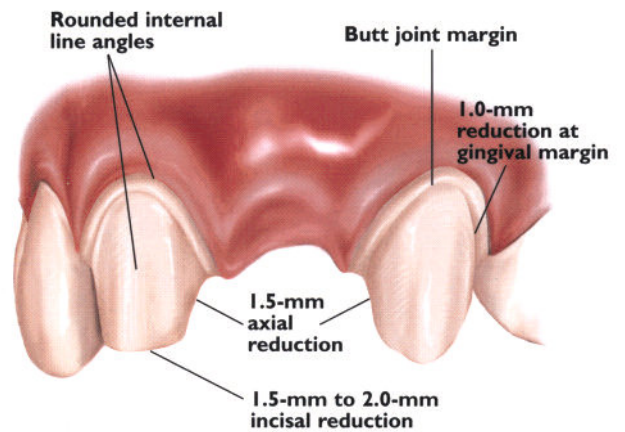
*"My goal, every day, every case, is to provide excellence in quality and service."  
Bill Volbeda, CDT*

## Anterior Restorations

### Crown Preparation



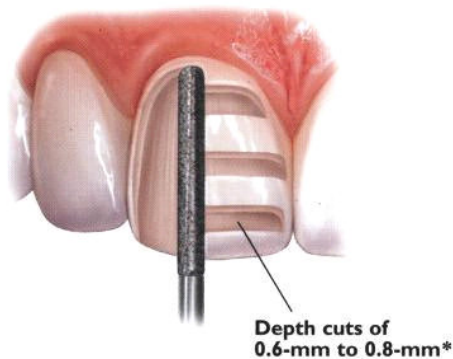
### Bridge Preparation



## Veneer Restorations

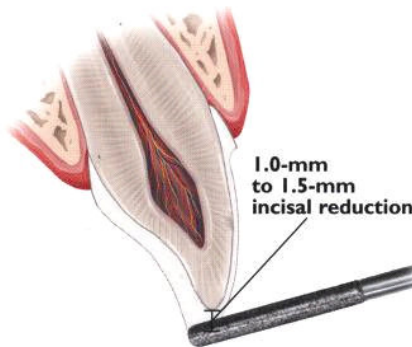
#### VENEER PREPARATION

A medium grit, round-ended, diamond bur is used to remove a uniform thickness of facial enamel by joining the depth-cut grooves



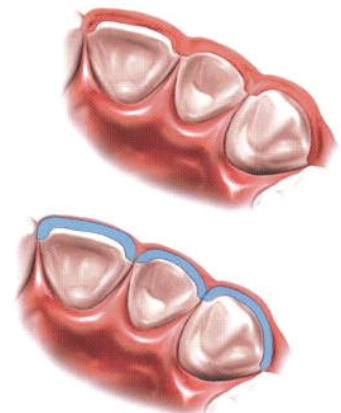
#### INCISAL PREPARATION

The diamond bur is angled to bevel back the incisal edge



#### CHAMFER MARGINS

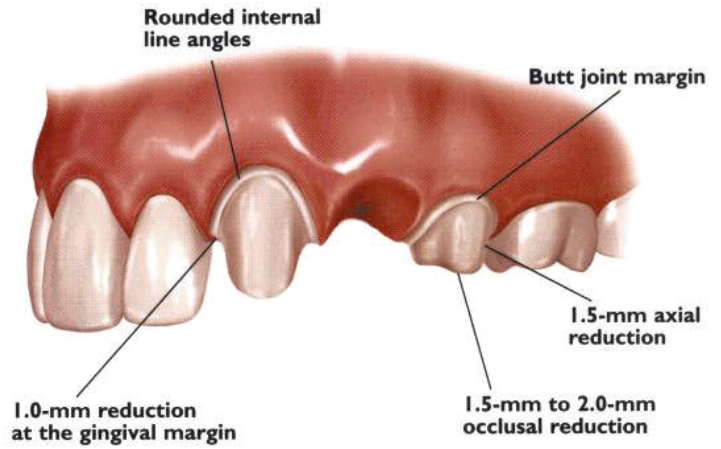
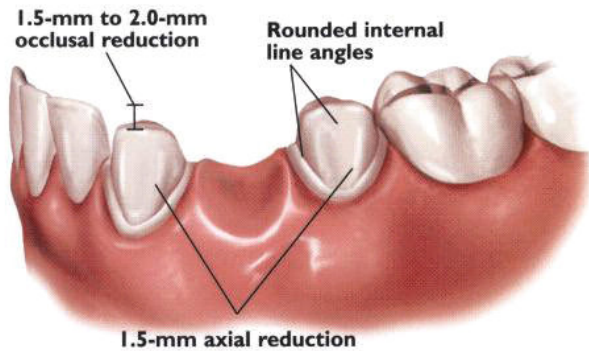
Correct preparation of the chamfer margins interproximally allows the appropriate bulk of porcelain




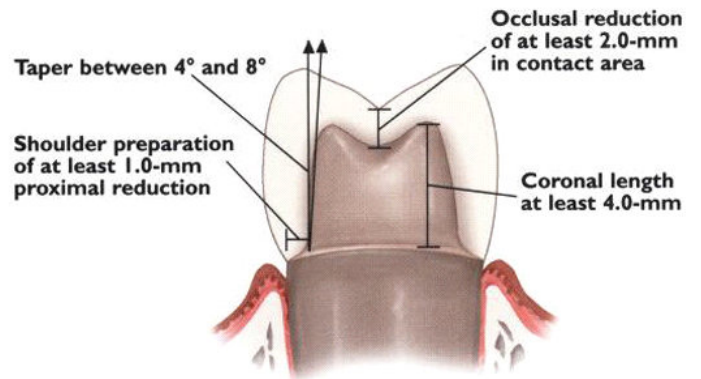
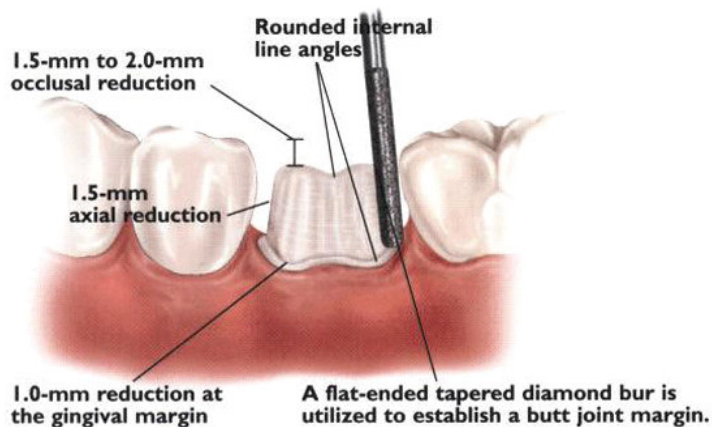
When porcelain margins are preferred, enhanced gingival esthetics can be achieved with a well defined 90 degree shoulder preparation.

# Posteriors Restorations

## Bridge Preparation



## Single Unit Preparation



5640 Moreno Street, Suite E  
Montclair, California, 91763  
Website: [www.valleydentallab.com](http://www.valleydentallab.com)  
Email: [valleydentallabinc@verizon.net](mailto:valleydentallabinc@verizon.net)

### Ceramic Restorations:

Ivoclar E-Max  
Pentron 3g OPC  
Dentsply Finesse  
Vita In-Ceram  
3m Lava  
Dentsply Cercon  
Shofu Halo

### Implant Restorations:

Astra  
Biomet 3i  
Friadent  
NobelBiocare  
Neoss  
Straumann ITI  
Zimmer

### Custom Digital Shading:

X-Rite ShadeVision  
Shofu ShadeEye EX

### Precision Attachments

**909-982-2266 800-427-3446**